

CARDIAC STUDY GUIDE

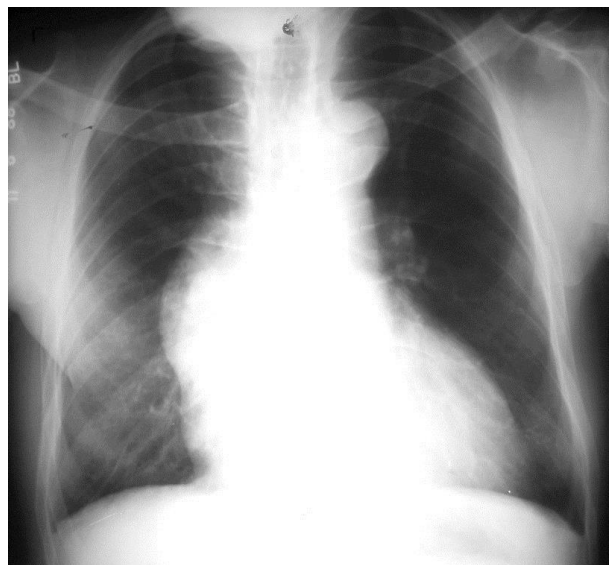
- Normal Anatomy and Physiology
 - Normal cardiac structures found on chest x-ray, CT, and MRI
 - Common variations in pulmonary venous and great vessel anatomy
- Basic techniques of cardiac CT and MRI, including limitations and common artifacts
- Thoracic Aorta and Great Vessels
 - Acquired aortic and great vessel disease (including dissection, aneurysm, intramural hematoma, penetrating ulcer, ulcerating plaques, sinus of Valsalva aneurysm, traumatic injury)
 - Congenital aortic and great vessel disease (including coarctation and pseudocoarctation, aortic arch/great vessel anomalies)
 - Takayasu arteritis and other vasculitides
 - Advantages and disadvantages of CT and MRI versus other techniques
- Ischemic and Nonischemic Heart Disease
 - Coronary artery anatomy on cardiac MRI and CT (including right, left main, left anterior descending, left circumflex, obtuse marginals, diagonals, acute marginals, septal perforators, myocardial bridging)
 - Coronary artery variants and anomalies
 - Atherosclerotic coronary artery disease
 - Imaging characteristics of myocardial infarction and its complications (including left ventricular failure, myocardial rupture, papillary muscle rupture, ischemic cardiomyopathy, left ventricular aneurysm and pseudoaneurysm, cardiac dyskinesis and akinesis)
 - Cardiomyopathy (including dilated, hypertrophic and restricted)
 - Arrhythmogenic right ventricular dysplasia
 - Benign cardiac tumors (including myxoma, lipoma, fibroma, rhabdomyoma)
 - Primary and metastatic malignant cardiac tumors (including angiosarcoma, rhabdomyosarcoma and lymphoma)
 - Cardiac calcifications
 - Congestive heart failure, Kerley lines
- Cardiac Valvular Disease (chest x-ray, CT, MRI)
 - MRI pulse sequences and appropriate imaging planes
 - Etiology and anatomic appearances of common valve disease
 - Quantitative measurements on MRI of pressure gradients, regurgitant fractions and valve area
- Pericardial Disease (including calcification, effusion, cyst, constrictive pericarditis, hematoma, metastases, partial and complete absence of the pericardium, pneumopericardium, and role of MRI and CT)

- Congenital Heart Disease in the Adult (chest x-ray, CT, and MRI)
 - Left-to-right shunts (including atrial septal defect, ventricular septal defect, partial anomalous pulmonary venous connection, patent ductus arteriosus) and Eisenmenger physiology
 - Tetralogy of Fallot and pulmonary atresia with ventricular septal defect
 - Congenitally corrected transposition of the great arteries
 - Persistent left superior vena cava
 - Manifestations of situs ambiguus
 - Ebstein anomaly
 - Cardiac malposition, including abnormal situs
 - Heart disease originally treated in childhood (including coarctation of the aorta, Tetralogy of Fallot and pulmonary atresia with ventricular septal defect, complete transposition of the great arteries, truncus arteriosus, common surgical corrections for congenital heart disease)
- Monitoring and Support Devices – “Lines and tubes” (including pulmonary artery catheter, intra-aortic balloon pump, pacemaker generator and leads, intracardiac defibrillator, atrial septal defect closure device, pericardial drain, central lines)
- Postoperative/Postprocedure Thorax (normal postoperative findings and complications)
 - Coronary artery bypass graft surgery
 - Cardiac valve replacement/transcatheter aortic valve replacement
 - Aortic graft
 - Aortic stent
 - Heart transplantation

SAMPLE QUESTIONS:

1. A 65-year-old man presents with atypical chest pain and shortness of breath. Based on the frontal chest radiograph, what is the most likely explanation?

- A) Aortic valve stenosis
- B) Hilar mass with malignant pericardial effusion
- C) Ascending aortic aneurysm with aortic regurgitation
- D) Congestive heart failure
- E) Chronic mitral regurgitation



Key = C

2. A 45-year-old woman presents with chronic fatigue and shortness of breath. Two slices from a CT scan of the chest are shown. What is the best explanation for the findings?

- A) Tricuspid endocarditis
- B) Atrial septal defect
- C) Pericardial constriction
- D) Biventricular heart failure
- E) Pulmonary hypertension

Key = E

