

THORACIC STUDY GUIDE

- Indications and Limitations of Imaging (chest x-ray, CT, MRI, ultrasound, PET/CT, fluoroscopy, V/Q, 3D, interventional)
- Physics and Safety
 - Magnification, scatter control, auto exposure control (AEC), contrast, noise, dose, safety, artifacts, acquisition parameters, temporal resolution, spatial resolution, reconstruction algorithms, MRI sequences
- Normal anatomy of lungs, mediastinum, and chest wall: identify normal structures and variants on chest x-ray, CT, MRI, and ultrasound
- Lung Lobes
 - Right Upper Lobe
 - Right Middle Lobe
 - Right Lower Lobe
 - Left Upper Lobe
 - Left Lower Lobe
 - Variants
- Lung Parenchymal Compartments
 - Axial/Central Interstitium
 - Septal/Peripheral Interstitium
 - Secondary Pulmonary Lobule
- Airway
 - Trachea
 - Main Bronchi
 - Lobar Bronchi
 - Segmental Bronchi
 - Subsegmental Bronchi
 - Variants (Tracheal Bronchus, Cardiac Bronchus)
- Hilum
 - Right
 - Left
- Pleura
 - Major Fissures
 - Minor Fissure
 - Surfaces (Mediastinal, Costal, Diaphragmatic)

- Interfaces
 - Anterior Junction Line
 - Posterior Junction Line
- Variants
 - Azygos Fissure
 - Superior Accessory Fissure
 - Inferior Accessory Fissure
 - Left Minor Fissure
 - Absent Minor Fissure
- Mediastinum
 - Thoracic Inlet
 - Superior Mediastinum
 - Anterior Mediastinum
 - Middle Mediastinum
 - Posterior Mediastinum
 - Azygoesophageal Recess
 - Right Paratracheal Stripe
 - Aortopulmonary Window
 - Paraspinal Line
 - Left Superior Intercostal Vein
- Pulmonary Arteries
 - Main Pulmonary Artery
 - Right and Left Pulmonary Arteries
 - Lobar Arteries
 - Segmental Arteries
 - Subsegmental and Smaller Arteries
- Bronchial Arteries
- Chest Wall
 - Soft Tissue
 - Bone
- Definition and Identification of Signs in Thoracic Radiology
 - Chest x-ray: air crescent, deep sulcus, continuous diaphragm, ring around the artery, fallen lung, flat waist, finger-in-glove, Golden S, luftsichel, Hampton hump, silhouette, cervicothoracic, thoracoabdominal, tapered margins, figure 3, fat pad/sandwich, scimitar, double density, hilum overlay, hilar convergence, juxtaphrenic peak, Westermark, positive bronchus, anterior bronchus
 - CT: CT angiogram, halo, reverse halo, signet ring, split pleura , comet tail, head cheese
- Diffuse Lung Disease
 - Emphysema (Centrilobular, Panlobular, Paraseptal, and Paracicatricial); Giant Bulla
 - Small Airways Disease (Asthma, Constrictive Bronchiolitis, Swyer-James Syndrome, Graft-versus-Host Disease, Respiratory Bronchiolitis, Follicular Bronchiolitis)
 - Bronchiectasis (Postinfectious, Cystic Fibrosis, Allergic Bronchopulmonary Aspergillosis, Dyskinetic Cilia Syndrome)
 - Lymphangiomyomatosis and Tuberous Sclerosis
 - Langerhans Cell Histiocytosis

- Birt-Hogg-Dube Syndrome
- Idiopathic Interstitial Pneumonia (UIP, NSIP, AIP, DIP, LIP, Organizing Pneumonia)
- Sarcoidosis
- Eosinophilic Pneumonia (Loeffler Syndrome, Acute and Chronic Eosinophilic Pneumonia, Hypereosinophilic Pneumonia)
- Collagen Vascular Disease (Rheumatoid Arthritis, Systemic Sclerosis, Systemic Lupus Erythematosus, Sjögren Syndrome, Mixed Connective Tissue Disease, Polymyositis/Dermatomyositis, Antisynthetase Syndrome)
- Pulmonary Alveolar Proteinosis
- Drug Toxicity
- Lymphangitic Tumor Spread
- Occupational Lung Disease (Asbestosis, Silicosis, Coal Worker Pneumoconiosis, Berylliosis)
- Vasculitis (Granulomatosis with Polyangiitis, Systemic Lupus Erythematosus, Microscopic Polyangiitis, Churg-Strauss Syndrome)
- Pulmonary Hemorrhage (Goodpasture Syndrome, Anticoagulation, Idiopathic Pulmonary Hemosiderosis)
- Noncardiogenic Pulmonary Edema (Near Drowning, Fluid Overload, Neurogenic, Inhalational Injury, Negative Pressure, Re-expansion)
- Cardiogenic Pulmonary Edema
- Lipoid Pneumonia
- Airway Diseases
- Malignancy
 - Adenocarcinoma
 - Adenoid Cystic Carcinoma
 - Mucoepidermoid Carcinoma
 - Squamous Cell Carcinoma
 - Carcinoid
 - Metastases
 - Other (Hamartoma, Chondroma, Papilloma, Papillomatosis)
- Other Endobronchial Abnormalities
 - Foreign Body
 - Mucus Plug
 - Aspiration
 - Broncholith
 - Allergic Bronchopulmonary Aspergillosis
- Stenosis/Narrowing
 - Postintubation
 - Granulomatosis with Polyangiitis
 - Sarcoidosis
 - Tuberculosis
 - Malacia
 - Fibrosing Mediastinitis
 - Amyloidosis
 - Relapsing Polychondritis
 - Tracheobronchopathia Osteochondroplastica

- Radiation
- Congenital
 - Bronchial Atresia
 - Tracheal Stenosis
- Trauma
- Collapsibility
- Tracheobronchomalacia
- Excessive Dynamic Airway Collapse
- Atelectasis
 - Compressive
 - Subsegmental
 - Segmental
 - Rounded
 - Right Upper Lobe Collapse
 - Right Middle Lobe Collapse
 - Left Upper Lobe Collapse
 - Lingula Collapse
 - Left Lower Lobe Collapse
 - Lung Collapse
- Devices
 - Endotracheal Tube
 - Tracheostomy
 - Stent
- Anatomic boundaries of anterior, middle, posterior and superior mediastinum; differential diagnosis of mediastinal mass based on location (on chest radiograph, CT, and MRI) and tissue characteristics (cystic, enhancing, calcified, fat containing); and differential diagnosis of bilateral hilar and mediastinal lymph node enlargement
- Anterior Mediastinal Mass
 - Thyroid Mass (goiter)
 - Thymic Mass (thymoma, thymic carcinoid, thymic cyst)
 - Lymphoma (non-Hodgkin, Hodgkin)
 - Germ Cell Tumor (teratoma, seminoma, nonseminomatous germ cell tumor)
 - Metastases
- Middle Mediastinal Mass
 - Bronchogenic Cyst
 - Foregut Duplication Cyst
 - Lymphoma
 - Metastases
 - Fibrosing Mediastinitis (idiopathic, infectious)
- Posterior Mediastinal Mass
 - Neurogenic Tumor (neurofibroma, schwannoma, neurofibromatosis, ganglioneuroma, ganglioneuroblastoma)
 - Neurenteric Cyst
 - Lymphoma
 - Spine-related Mass/Infection

- Metastases
- Thoracic Inlet
 - Goiter
 - Lymphangioma
- Esophagus
 - Esophageal Cancer
 - Achalasia
 - Varices
 - Diverticulum
 - Duplication Cyst
 - Esophagitis
 - Postprocedure (stent, esophagectomy)
 - Devices (feeding tube, gastric drainage tube, manometer, pH probe, Sengstaken-Blakemore [Minnesota] tube)
- Lymph Node Enlargement
 - Lymphoma
 - Sarcoidosis
 - Infection
 - Metastases
 - Occupational Exposure (silicosis/coal worker pneumoconiosis, berylliosis)
- Systemic Veins
 - Occlusion
 - Stenosis
 - Collaterals
 - Devices (central line, extracorporeal membrane oxygenation [ECMO] cannula, stent)
- Pneumomediastinum
- Benign and malignant neoplasms of the lung
- Histology
 - Small Cell Carcinoma
 - Adenocarcinoma (in situ, minimally invasive, invasive lepidic predominant, invasive, invasive mucinous)
 - Squamous Cell Carcinoma
 - Large Cell Carcinoma
 - Neuroendocrine (typical carcinoid, atypical carcinoid, large cell neuroendocrine carcinoma)
 - Primary Pulmonary Lymphoma (mucosa-associated lymphoid tissue [MALT], bronchus-associated lymphoid tissue [BALT], Epstein Barr virus [EBV]-related, lymphomatoid granulomatosis)
 - Metastases
 - Benign Tumors/Masses (intralobar and extralobar sequestration, congenital pulmonary airway malformation, hamartoma/mesenchymoma, plasma cell granuloma, chondroma)
- Imaging findings
 - Solitary Pulmonary Nodule
 - Lung Mass
 - Hilar Mass
 - Superior Sulcus Tumor

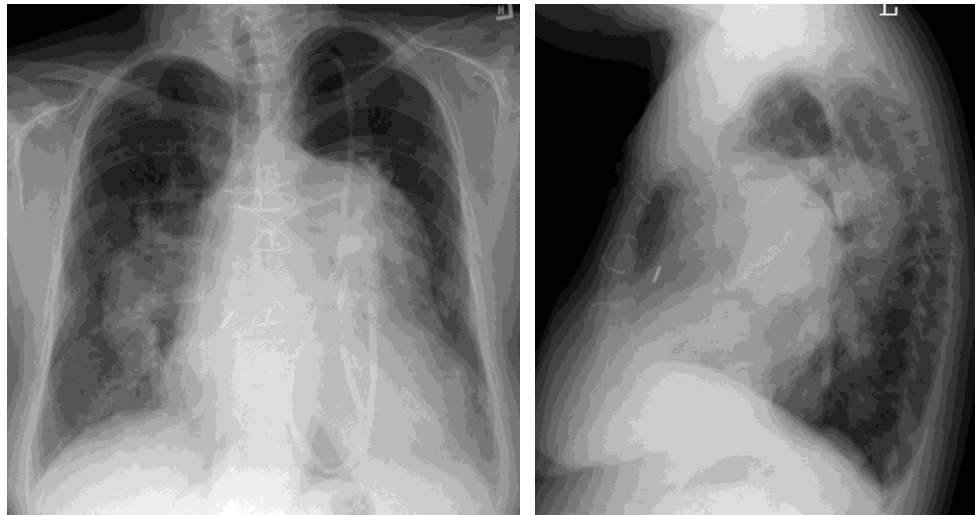
- Endobronchial Mass
- Lobar or Lung Collapse
- Chronic Focal Consolidation
- Imaging Role
 - Screening (asymptomatic)
 - Diagnosis (symptomatic)
 - Staging (T, N, M)
- Imaging Techniques
 - Chest Radiography
 - Fluoroscopy
 - CT
 - MRI
 - PET-CT
 - SPECT
 - Imaging-Guided Diagnosis (fine-needle aspiration, core needle biopsy, indications/appropriateness, complications)
 - Image-Guided Therapy (ablation)
- Trauma to the Lung
 - Contusion
 - Shear Injury
 - Laceration
 - Pneumatocele
 - Interstitial Emphysema
 - Lung Herniation into Chest Wall
 - Fat Emboli
 - Postprocedure (surgical lung biopsy, wedge resection, lobectomy, pneumonectomy, lung volume reduction surgery, lung transplantation, radiation therapy, reconstruction flaps)
- Chest Wall
- Trauma
 - Rib Fracture (flail chest)
 - Sternal Fracture
 - Spine Fracture (osteoporosis with compression fractures)
 - Clavicle Fracture; Acromioclavicular Joint Dislocation
 - Shoulder Fracture/Dislocation
- Congenital (Poland syndrome, Sprengel deformity)
- Masses (Langerhans cell histiocytosis, multiple myeloma/plasmacytoma, fibrous dysplasia)
- Rib Abnormalities
 - Rib Notching (coarctation of the aorta, rheumatoid arthritis)
 - Ribbon Ribs (neurofibromatosis)
- Spine Abnormalities
 - H-shaped Vertebral Bodies (sickle cell disease)
 - Posterior Scalloping of the Vertebral Bodies
 - Vertebra Plana
- Postoperative
 - Chest Wall Reconstruction/Prosthesis

- Breast Implants
 - Muscle Flap
- Diaphragm
- Hernia
 - Bochdalek
 - Morgagni
 - Hiatal
- Paralysis
- Rupture
- Pleura
- Malignancy
 - Mesothelioma
 - Metastases
 - Lymphoma
- Benign Tumors
 - Solitary Fibrous Tumor
 - Lipoma
- Infection
 - Empyema
 - Empyema Necessitatis
 - Fibrothorax
- Effusion
 - Transudate vs. Exudate
 - Hemothorax
 - Chylothorax
 - Mobile vs. Loculated
- Pneumothorax
 - Spontaneous
 - Secondary (diffuse lung disease, trauma, endometriosis [catamenial])
 - Tension
- Asbestos-related Disease
 - Effusion
 - Thickening
 - Plaques
- Percutaneous Intervention
 - Indications/Appropriateness
 - Complications
 - Aspiration
 - Drain Placement
 - Lytic Therapy
- Postprocedure
 - Pleurodesis
 - Eloesser Flap/Clagett Window
- Devices
 - Large Bore Pleural Drain

- Pigtail Catheter
- Infection and Immunity
- Immunocompetent
- Immunocompromised
 - HIV
 - Hematopoietic Stem Cell Transplant
 - Lung Transplant
- Bacterial
 - Staphylococcus Aureus
 - Streptococcus Pneumoniae
 - Mycoplasma Pneumoniae
 - Klebsiella Pneumoniae
 - Pseudomonas Aeruginosa
 - Legionella Pneumophila
 - Tuberculosis
 - Nontuberculous Mycobacteria (Mycobacterium avium complex, Hot tub pneumonitis)
 - Nocardia
 - Actinomycosis
- Fungal
 - Aspergillus (invasive, chronic necrotizing, aspergilloma, allergic bronchopulmonary aspergillosis)
 - Mucor
 - Pneumocystis Jiroveci
- Viral
 - Cytomegalovirus (CMV)
 - Varicella
 - Respiratory syncytial virus (RSV) 1
 - Adenovirus
 - Influenza Virus (H1N1 influenza virus)
 - Human Metapneumovirus
 - Parainfluenza Virus
- Aspiration Pneumonia
- Septic Emboli
- Pulmonary Vasculature
- Primary Pulmonary Hypertension
- Secondary Pulmonary Hypertension
 - Diffuse Obstructive or Restrictive Lung Disease
 - Cardiac Valvular Disease
 - Intracardiac Shunt Lesion
 - Chronic Pulmonary Embolism
- Arteriovenous Malformation
 - Isolated
 - Osler-Weber-Rendu Syndrome
- Aneurysm
- Pseudoaneurysm
 - Traumatic (catheter related)

- Mycotic
- Ipsilateral Small Pulmonary Artery
 - Proximal Interruption
 - Swyer-James Syndrome
- Tumors
 - Sarcoma
 - Intravascular Metastases
- Arteritis
 - Takayasu Arteritis
 - Williams Syndrome
 - Behçet Disease
- Devices
 - Pulmonary Artery Catheter
- Pulmonary Embolism
 - Acute
 - Chronic

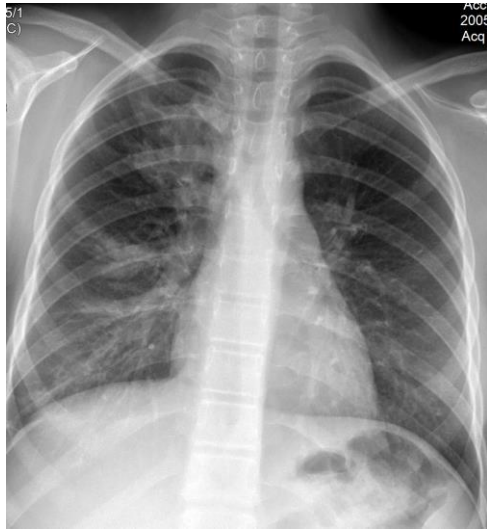SAMPLE QUESTIONS



1. What is the most likely diagnosis?

- A. Sarcoidosis
- B. Pulmonary hypertension
- C. Aortic coarctation
- D. Tuberculosis

Key B. Pulmonary hypertension



2. What radiologic sign is shown?

- A. Figure 3
- B. Westermark
- C. Finger-in-glove
- D. Silhouette

Key C. Finger-in-glove