



Neuroradiology Subspecialty Exam Study Guide

The exam will consist of three equal parts; Brain, Spine and Head & Neck. Pediatric cases are included within each exam section. Each section will consist of 60 scorable units (i.e. individual questions) for a total of 180 items. There are several formats for case presentation (see sample questions below). The most common format will be multiple choice questions. In this format, each case will start with an image or set of images with accompanying clinical information. Candidates will be asked to choose the most likely (or on occasion the LEAST likely) diagnosis. After the candidate makes her/his choice, one to three follow-up questions will typically be asked. The candidate will have the opportunity to go back and review the original images but will be blocked from changing her/his answer to prior question(s). The follow-up questions will probe the candidate's knowledge of clinical, pathologic and therapeutic aspects of the disease entities introduced in the first question. It is important to note that follow-up questions may refer to entities other than the "correct" diagnosis of the case. In some circumstances follow-up questions will include additional imaging studies that may alter the likely diagnosis of the case. This format is thus very similar to that used in the previous oral Subspecialty exam. Another format is an item matching case. In this format the candidate will be given a list of diagnostic options and sets of images. The candidate will match the images to the correct diagnosis. This format is used to test the candidate's ability to differentiate between lesions with similar appearances or locations. The third format will be for anatomy questions. The candidate will be shown an image and will be asked to place a label over a specific anatomic structure.

If a candidate fails one component of the exam, they may retake this component of the exam ("Condition"). If a candidate fails two or three components of the exam, they will have to repeat the entire exam. In either scenario, this will only be possible if there is another exam administration within the candidate's board eligibility period. Because of the length of the exam, there will be the opportunity to explore a broad sample of cases. The case mix will reflect the typical clinical practice of a neuroradiologist. Thus the majority of the cases will be examples of relatively common entities, but the follow-up questions will require a greater depth of knowledge than that expected of a general radiologist. For instance if a brain tumor is shown, the candidate might be asked follow-up questions concerning WHO classification, prognosis and/or treatment

The exam will sample the entire domain of neuroradiology. The ABR team of Neuroradiologists has compiled a list of entities felt to encompass our field and this list will be available to candidates. One way to think about the types of exam questions is to ask: "What distinguishes a neuroradiologist from a general radiologist who does some neuroradiology?" We expect a neuroradiologist to be: a) familiar with a broader range of pathologic entities including some relatively uncommon diseases; b) more knowledgeable about the physics involved and image optimization for neuroradiology exams and procedures; c) able to recognize artifacts on neuroimaging exams and procedures; d) extremely familiar with therapeutic options for brain, spine and

head and neck diseases; and e) understand the imaging appearances of therapeutic interventions. It is expected that neuroradiologists will have knowledge of advanced imaging techniques including DTI, MR Spectroscopy, Perfusion (CT and MR), fMRI and PET/CT in the diagnosis of diseases and to be able to interpret these exams in the context of clinical cases. Since the neuroradiologist will be dealing with allied specialists (neurologists, neurosurgeons, ophthalmologists and ENT surgeons) we expect him/her to be familiar with nomenclature and classification schemes used by these specialists and to function as the imaging expert as occurs in advanced interdisciplinary clinical conferences (e.g., tumor board). Finally a neuroradiologist should be able to function as an expert consultant to other radiologists and allied clinicians for cases with unusual or rare imaging findings.

Outlined below is a general list of the topics in Neuroradiology that may be covered in a module. Please note that this list covers basic themes and concepts and does not encompass every specific entity that could possibly be covered in a module.

BRAIN

- ✓ Anatomy and Variants
- ✓ Artifacts
- ✓ Neoplasm
 - Common and Uncommon Entities
 - Therapeutic Options
 - Treatment Effects
 - Advanced Imaging Modalities (PET/CT, MR Perfusion, MR spectroscopy, Surgical planning with DTI and fMRI)
 - Knowledge of Natural History of Diseases
 - Knowledge of Genetics of Brain Tumors as it Relates to Prognosis and Treatment Options
- ✓ Vascular Disease
 - Infarction, Hemorrhage, Vasculopathy, Vascular Lesions (AVM Aneurysm DVA cavernoma etc., Venous Disease)
 - Indications and Contraindications for Various Therapeutic Options
 - Vascular Imaging Techniques (including CT, MR, CTA, MRA, MRV, catheter angiography, CT/MR perfusion etc.)
- ✓ Trauma
 - Indications for Use of Advanced Techniques (including CTA/MRA, DTI, SWI, & Perfusion)
 - Imaging of Minor TBI
- ✓ White Matter Disease
 - Demyelinating, Ischemic, Inflammatory, Metabolic, Genetic
 - Classification of MS and Imaging Criteria for Diagnosis
 - Temporal Changes
 - Pathophysiology of Demyelinating Diseases
 - Advanced Imaging Technique – DTI, MRS, Perfusion
- ✓ Infectious/inflammatory Diseases
 - Findings in Immunocompetent and Immunocompromised Patients
 - Types of Infections
 - Temporal Changes
 - Treatment Options and Prognosis
 - Advanced Imaging Techniques – MRS, Perfusion,
- ✓ Metabolic
 - Genetic
 - Toxins
 - Drug Reactions
 - Nutritional
- ✓ Congenital/Developmental
 - Structural Abnormalities
 - Metabolic Abnormalities
 - Role of Advanced Imaging Tools
 - MRS, Perfusion, DTI
- ✓ Neurocutaneous Syndromes
- ✓ Neurodegenerative Disorders
- ✓ Perinatal and Neonatal Disorders

- ✓ Role of Advanced Imaging Tools

SPINE

- ✓ Anatomy and Variants
- ✓ Artifacts
- ✓ General
 - Choice of Imaging Options in Various Clinical Situations
 - Appearance of Post-operative Findings
 - Appearance of Surgical Hardware
 - Findings Indicative of Hardware Failure
- ✓ Degenerative Spine Disease
 - Common and Uncommon Entities
 - Nomenclature for Description of Discogenic Disease
 - Findings Indicative of Instability
 - Failed Back
- ✓ Inflammatory and Other Arthritides (non-degenerative)
- ✓ Trauma
 - Description of Fractures
 - Classification schemes commonly used by neurosurgeons and orthopedic surgeons
 - Findings Indicative of Instability
 - Soft Tissue Injuries
 - Spinal Cord Injury
 - Hemorrhage
 - Chronic Post-traumatic Changes
- ✓ Infection and inflammation
 - Vertebral Column
 - Intraspinal
 - Extradural
 - Intramedullary
- ✓ Demyelinating and Metabolic Processes
- ✓ Vascular
 - Ischemia
 - Hemorrhage
 - Vascular Malformations
- ✓ Neoplastic
 - Extradural
 - Primary and Secondary
 - Treatment Options
 - Intradural, Extradural
 - Intramedullary
- ✓ Congenital, Developmental and Genetic Disorders

HEAD AND NECK

This portion of the exam includes cases from the various regions that are subsumed under Head and Neck Radiology. This is an area where general radiologists often have limited experience and expertise and therefore neuroradiologists are expected to play a pivotal role in diagnosing diseases of these regions. The choice of imaging modality and protocols is critical to diagnosis and the neuroradiologist is expected to be familiar with the advantages and disadvantages of different modalities in different clinical situations.

The following general regions will be covered:

- ✓ Orbit
- ✓ Sinonasal Cavity/Facial Bones
- ✓ Skull Base (including sella)
- ✓ CP Angle/IAC
- ✓ Temporal Bone
- ✓ Suprahyoid Neck
- ✓ Infrahyoid Neck

For each region you can expect questions potentially concerning:

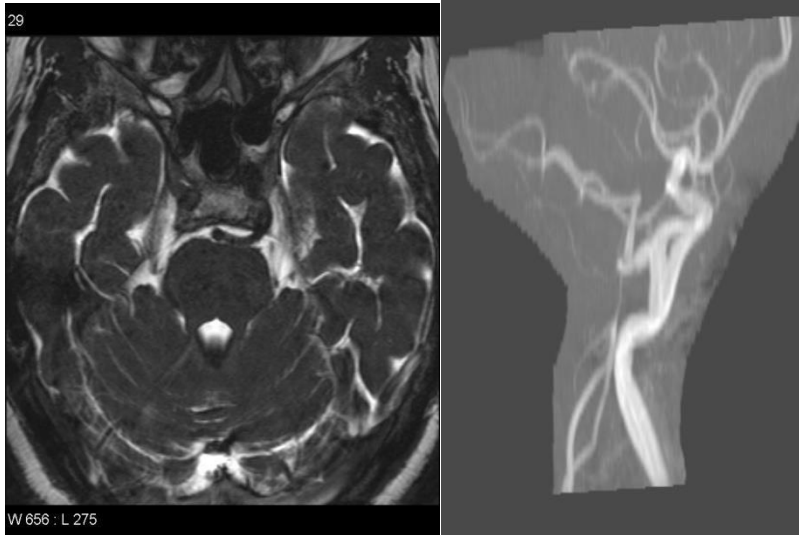
- ✓ Normal Anatomy and Variants
- ✓ Artifacts
- ✓ Neoplasm (including staging issues)
- ✓ Infection/Inflammation
- ✓ Metabolic Abnormalities
- ✓ Congenital/Genetic Abnormalities
- ✓ Trauma
- ✓ Post-operative Change Including Reconstruction
- ✓ Non-surgical Treatment Effects
- ✓ Recurrent Disease
- ✓ Imaging Artifacts

SAMPLE QUESTIONS

The following sample questions are examples of what you may see on the exam.

SINGLE-ANSWER MULTIPLE CHOICE QUESTION:

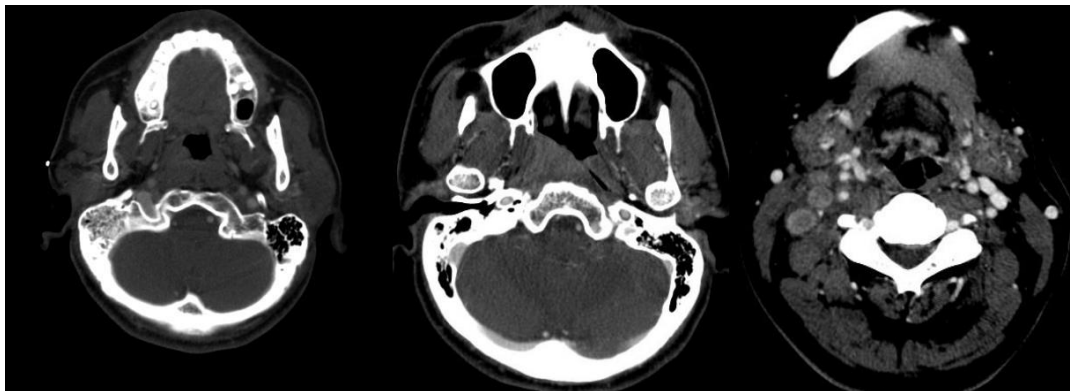
1. A 72-year-old patient presents with left facial pain. The images show what vascular anomaly?



- A. Persistent trigeminal artery
- B. Persistent hypoglossal artery
- C. Persistent dorsal ophthalmic artery
- D. Persistent primitive olfactory artery

SINGLE-ANSWER MULTIPLE CHOICE QUESTION WITH BLOCKED FOLLOW-UP QUESTION:

2a. A 51-year-old Chinese man has a 1-year history of otalgia. He presents with a palpable neck mass. Based on the images, in addition to lymphadenopathy, what is the most likely diagnosis?



- A. Mastoiditis
- B. Nasopharyngeal carcinoma

- C. Supraglottic carcinoma
- D. Cat scratch disease

BLOCKED RETURN: The candidate cannot go back and change their answer after proceeding to the next question. But one can go back and review the question and images.

5b. Nasopharyngeal carcinoma is most commonly associated with which of the following infections?

- A. Epstein-Barr virus
- B. Varicella zoster virus
- C. Parvovirus
- D. Human papillomavirus
- E. Coxsackie virus

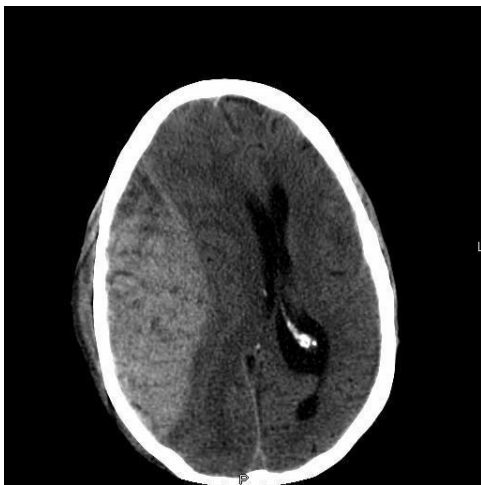EXTENDED MATCHING OR "R-TYPE" QUESTION:

3. For each patient, select the most likely clinical scenario. Each option may be used once, more than once, or not at all.

Option List:

- A. 3-year-old child with altered mental status
- B. 10-year-old child with seizures since birth
- C. 30-year-old patient involved in a motor vehicle collision, no skull fracture
- D. 70-year-old patient with history of multiple falls
- E. Acute mental status change, dehydration
- F. Dementia
- G. Severe hypertension with sudden headache
- H. Trauma with skull fracture
- I. "Worst headache of life"

3a. Patient A.



3b. Patient B.

