

## **VASCULAR/INTERVENTIONAL STUDY GUIDE**

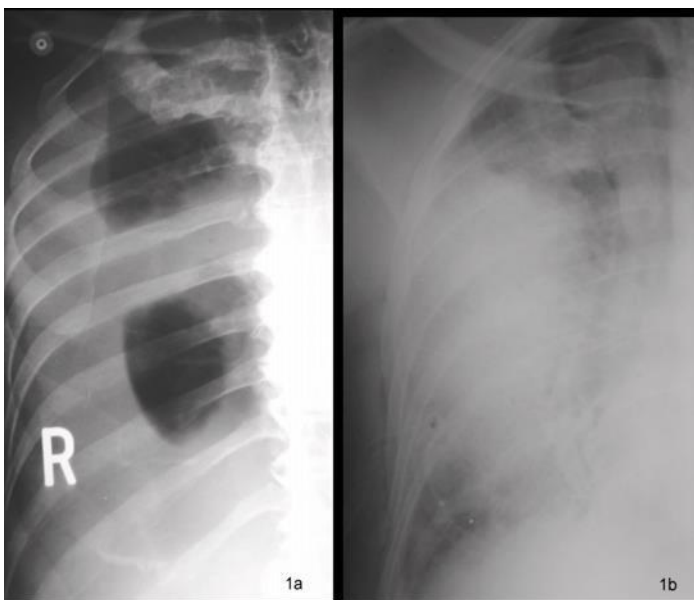
- Vascular diagnosis
  - CT and CT angiography
  - MRI and MR angiography
  - Noninvasive vascular lab
    - Vascular ultrasonography (including venous and arterial color flow imaging, Doppler, ankle-brachial indices, segmental limb pressures)
    - Pulse volume recordings (PVRs)
  - Arteriography (including thoracic aorta, brachiocephalic arteries, carotids; upper extremity arteries; lower extremity arteries; abdominal aorta and its branches; pelvic arteries; mesenteric arteries and their branches; renal arteries and their branches; miscellaneous arteries such as intercostals, internal mammary, spinal, etc.; collateral pathways; hemodynamics)
  - Venography and venous sampling (including head and neck; upper extremity veins; lower extremity veins; pelvic veins; gonadal veins; hepatic veins; portal and mesenteric veins; superior vena cava; inferior vena cava; collateral pathways; miscellaneous such as mediastinal, azygos, parathyroids, etc.; hemodynamics)
  - Pulmonary angiography (including pulmonary arteries and veins; hemodynamics)
  - Dialysis access evaluations
  - Lymphangiography
- Vascular intervention
  - Venous access (tunneled, nontunneled, ports)
  - Inferior vena cava filter placement and retrieval
  - Foreign body retrieval
  - Dialysis access intervention
  - TIPS and TIPS evaluation/revision
  - Peripheral (and central) venous and arterial angioplasty/stents (including peripheral venous and mesenteric)
  - Miscellaneous venous interventions
  - Carotid stenting
  - Pharmacologic and other thrombolytic therapy, thrombectomy devices
  - Atherectomy, lasers, cryoplasty, filter wires
  - Venous ablation (varicose veins) Aortic endografting (thoracic, abdominal)

- Emergency embolization (trauma, GI bleed, hemoptysis, pseudoaneurysm, other)
- Transcatheter infusion therapy (e.g., vasopressin, papaverine)
- Thrombectomy
- Elective embolization (uterine fibroids, varicoceles, pelvic congestions, portal vein, vascular malformations, endoleak, etc.)
- Direct injection therapy of venous malformations (e.g., ethanol, ethanolamine oleate)
- Chemoembolization (transcatheter arterial chemoembolization [TACE])
- Radioembolization (selective internal radiotherapy)
- Miscellaneous arterial interventions
- Transvenous biopsy
- Nonvascular intervention
  - Biopsy (including lung, bone, liver, kidney, adrenal, pancreas, mediastinum, retroperitoneum, other; all modalities)
  - Abscess drainage, tube checks, catheter management (including empyema)
  - Paracentesis, thoracentesis
  - Thoracostomy
  - Pleurodesis
  - Tunneled catheter drainage of refractory pleural effusion or ascites
  - Biliary interventions (including percutaneous transhepatic cholangiography [PTC], drainage, stents, biopsy, tube checks and exchanges, dilation)
  - Percutaneous management of retained common bile duct stones
  - GU interventions (including nephrostomy, nephroureterostomy, tube checks and exchanges, nephrostolithotomy tract establishment and dilatation)
  - Ureteral intervention (including ureteroplasty, ureteral stents)
  - Gastrostomy and gastrojejunostomy (including tube checks and exchanges)
  - Cholecystostomy (with tube checks and exchanges)
  - Cyst/lymphocele aspiration, drainage, sclerosis (including tube checks and exchanges)
  - Nonvascular stents (including esophageal, tracheobronchial, duodenal, colonic)
  - Transplant interventions
  - Tumor ablation (including radiofrequency ablation, laser, microwave, cryoablation, ethanol, combination therapy)
  - Pain management
  - Vertebroplasty, kyphoplasty
  - Fallopian tube recanalization
- Categories of diseases and conditions (including congenital/genetic, normal variants, inflammatory, infectious, neoplastic, atherosclerotic, degenerative, thromboembolic, hypertensive, dysplastic, iatrogenic, traumatic, idiopathic, radiation-induced, compressive such as May-Thurner, thoracic outlet syndrome [TOS], median arcuate ligament, other)
- Clinical and related nonprocedural activities
  - Hospital inpatient care (admission, history and physical, orders, management, discharge)
  - Inpatient consults

- Outpatient practice (including new patient referrals, follow-up postintervention)
- Quality and safety activities (QA committee service, practice performance improvement)
- Professionalism
- Principles of life support
- Principles of image quality
- Contrast material (including nephropathy and nephrogenic systemic fibrosis)
- Conscious sedation
- Regulatory matters (including HIPAA, other)
- Risk management
- Other

### SAMPLE QUESTIONS:

A 65-year-old man with a malignant pleural effusion and dyspnea is referred for therapeutic thoracentesis. Image 1a is obtained preprocedure. Image 1b is obtained 30 minutes postprocedure when the patient reports severe worsening of dyspnea. Which of the following is the most likely diagnosis for image 1b?



- A. Pneumothorax
- B. Reexpansion pulmonary edema**
- C. Pleural hemorrhage
- D. Aspiration pneumonia
- E. Empyema

### BLOCK RETURN

For reexpansion pulmonary edema, respond "true" (T) to each correct statement. Respond "false" (F) to each incorrect statement.

**T/F** The likelihood of this complication rises with the volume of fluid withdrawn.

Updated 8/11/2025

NOTE: Study Guides may be updated at any time.

- T/F** Slow withdrawal of fluid makes this complication less likely.
- T/F** Patients who have recently developed pleural effusion are more likely to experience this complication than those with chronic pleural effusions.
- T/F** Intubation with positive pressure ventilation may be necessary for treatment.